

症例

济生会熊本病院 中央検査部 岩代 翔吾

症 例

年齢・性別：80代 男性

主訴：残尿感

既往歴：肺癌

現病歴：前立腺肥大症のため当院泌尿器科通院中に尿蛋白、免疫グロブリンの異常を指摘され、当院腫瘍内科を受診。

生化学

Na	143mEq/L
K	3.69mEq/L
Ca	9.1mg/dL
TP	8.7g/dL
ALB	3.3g/dL
IgG	3597mg/dL
IgA	26mg/dL
IgM	19mg/dL
AST	22IU/L
ALT	16IU/L
LD	164IU/L
T-Bil	0.8mg/dL

尿定性

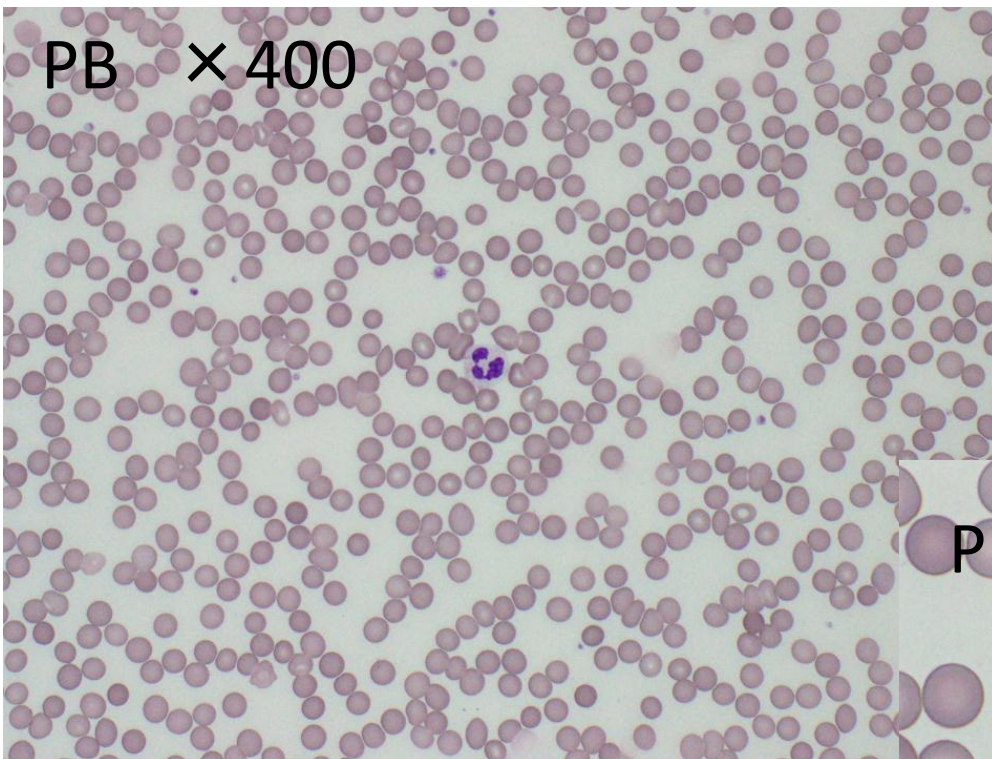
pH	5.5
蛋白	(+)
蛋白半定量	70mg/dL
糖	(2+)
糖半定量	150mg/dL
ケトン体	(-)
潜血	(3+)

血液検査

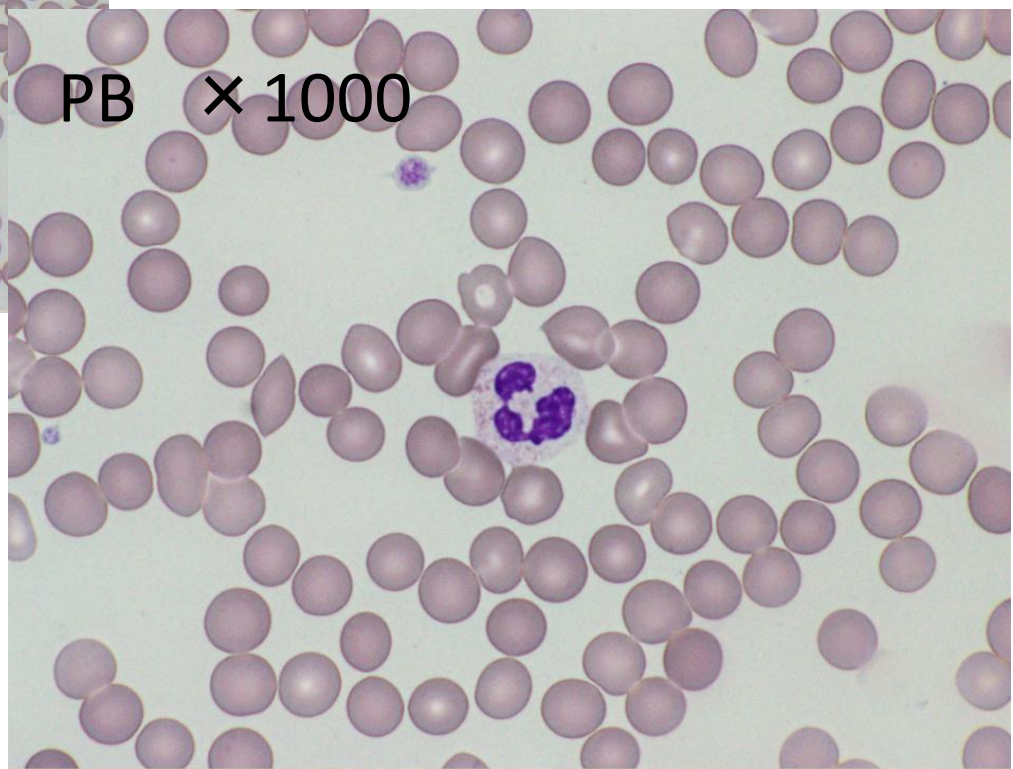
WBC	$55 \times 10^2 / \mu \text{L}$
RBC	$361 \times 10^4 / \mu \text{L}$
Hb	11.0g/dL
Hct	33.3%
MCV	92.2fL
MCH	30.5Pg
MCHC	33.0%
PLT	$15.8 \times 10^4 / \mu \text{L}$

Baso	0.0
Eo	1.0
Stab	16.0
Seg	64.0
Lympho	13.0
Mono	5.0
Aty-Ly	1.0

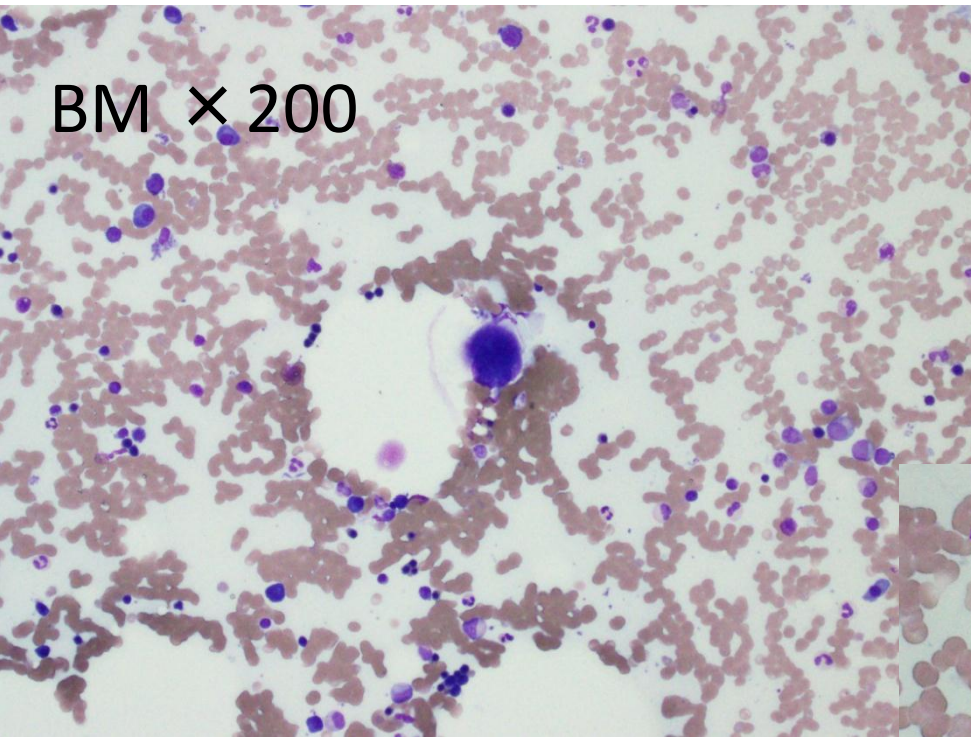
PB × 400



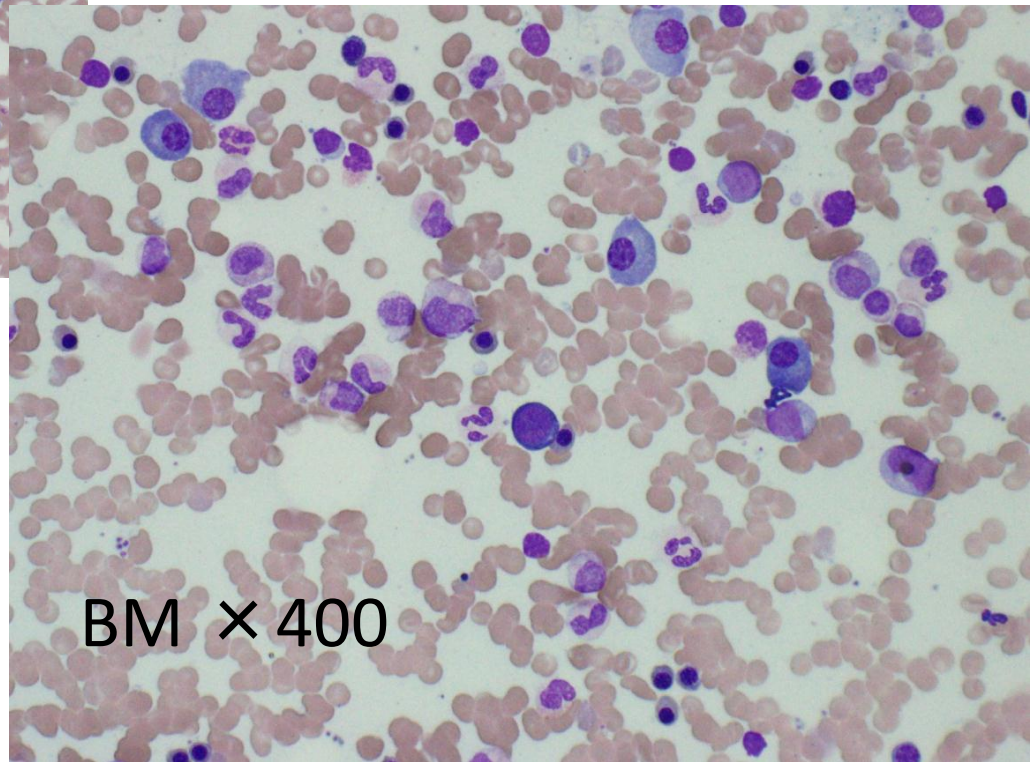
PB × 1000



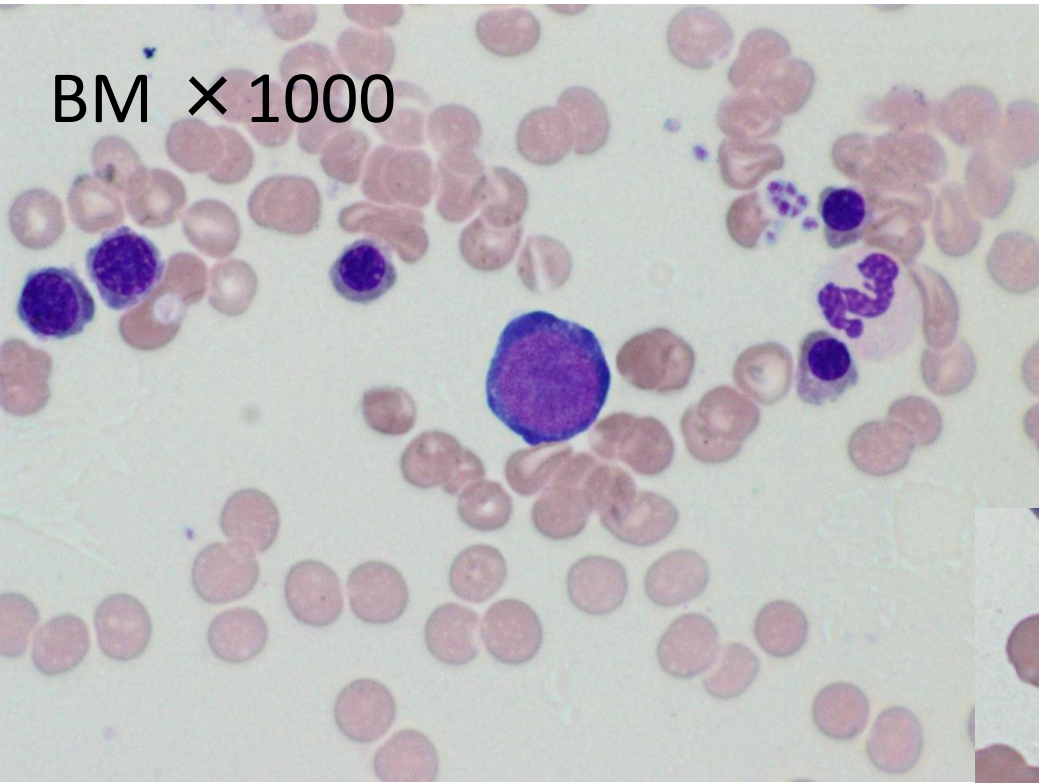
BM × 200



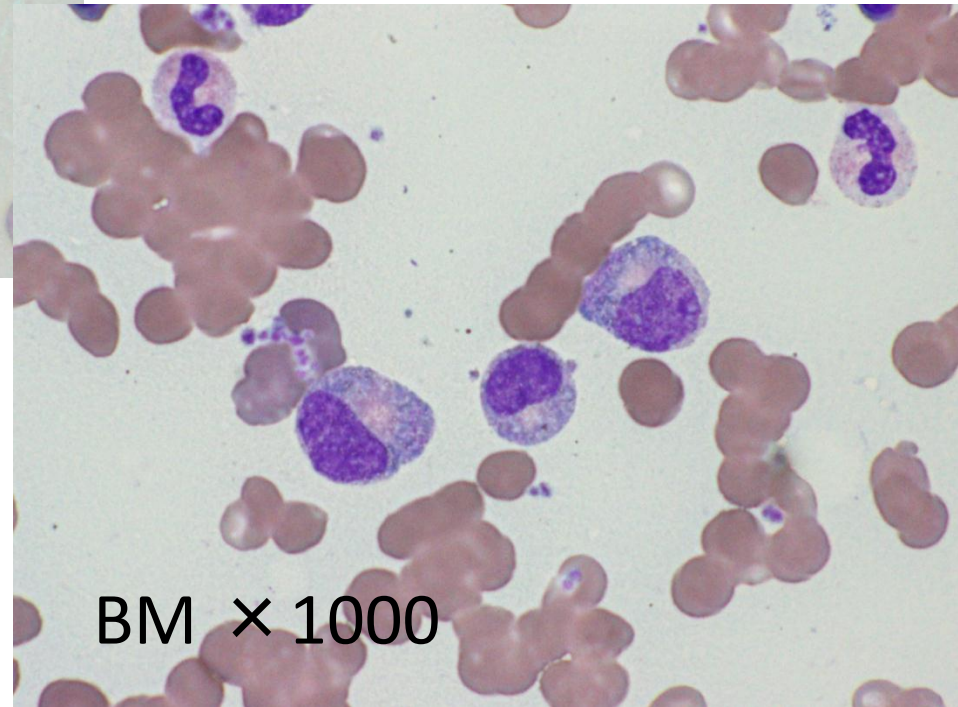
BM × 400



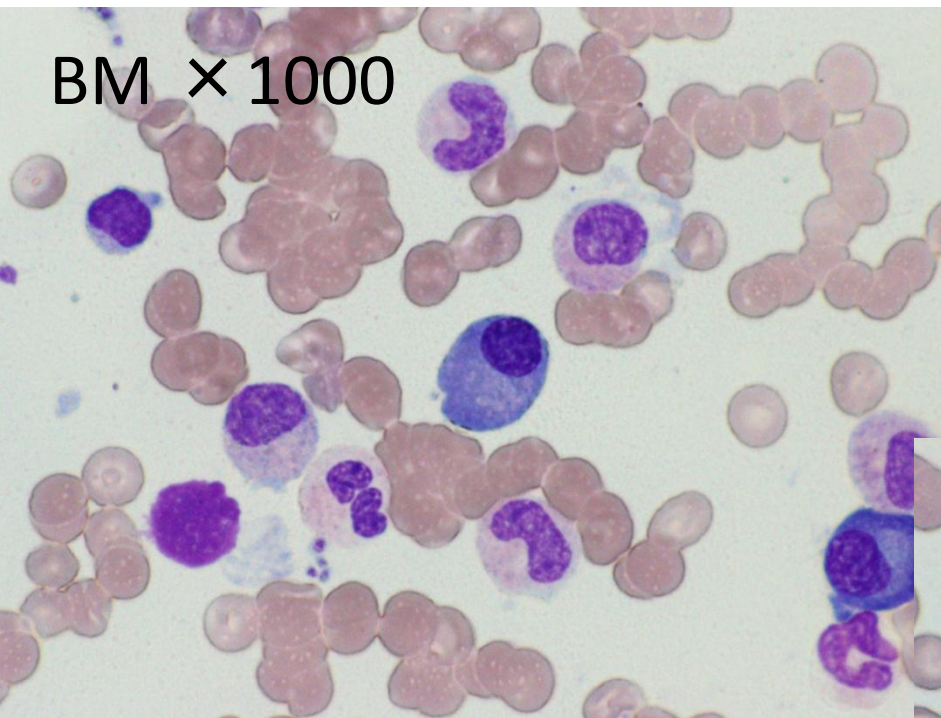
BM × 1000



BM × 1000



BM × 1000



BM × 1000

